

Chapter 2 Background and Method Overview

The cardiac left ventricle is one of the most crucial and thoroughly studied structures in the human body. The unique new capabilities of Real Time 3D (RT3D) ultrasound to measure geometric properties of the beating heart is therefore particularly exciting. This chapter begins with a justification of the clinical goal of determining left ventricular (LV) volume and follows with a general review of cardiac imaging methods comparing the abilities and limitations of RT3D ultrasound to other imaging modalities. Given an RT3D image of the heart, analytical techniques for identifying and measuring the shape of the left ventricle are then reviewed, putting the development of the present method of analysis into the context of other approaches. The chapter concludes with a diagrammatic overview of the method for identifying and measuring the LV that will be described in detail in subsequent chapters.

2A. Imaging of Cardiac Anatomy and Function

RV and LV Anatomy and Function

The primary function of the heart is, naturally, to circulate the blood. In this crucial function the heart is assisted during inspiration by negative intrathoracic pressure transmitted to the right ventricle (RV) and during upright walking by the skeletal muscles and venous valves of the legs. Artificial assistance to circulation can be given by chest compressions during cardiopulmonary resuscitation or by external or implanted pumps. However, under normal conditions the heart is the body's primary and indispensable mover of blood.

Healthy cardiac contraction generally causes concentric sections of the myocardial wall to move inward, thereby decreasing the volume of the respective cardiac chamber and forcing blood out through the appropriate valve. Impaired or dead myocardial tissue may still move inward by being dragged passively by neighboring healthy tissue, but this occurs without the normal increase in wall thickness. Thus, as a pump the heart may be analyzed via imaging data by determining the position of the valves and the motion and thickness of the myocardium.

The right and left sides of the heart each consist of an atrium and a ventricle, with valves situated before and after each respective ventricle to convert periodic contractions into net blood flow. Beyond these similarities, however, striking differences are evident in structure and function between the right and left sides. The LV must generate high pressure to overcome the resistance of the systemic circulation. It typically contains the great majority of cardiac muscle configured in a roughly cylindrical shape. By contrast, the right ventricle (RV), only facing the low resistance of the capillary beds in the lungs, typically has a thin myocardium and a flattened shape that curves around the LV. Blood flows through the RV and the LV in series, with virtually the entire output of the RV returning to the left atrium (LA). Assuming perfect valves that prevent back flow, Kirchhoff's law guarantees that average blood flow through the two sides of the heart is equal, though instantaneous flow differs between the RV and LV due to the changing capacity of the lungs during inspiration and expiration.

Many methods exist, besides imaging, that can measure cardiovascular function. A physician trained in the use of the stethoscope can, for example, monitor the pulmonary compliance by listening to the interval between the sounds of the aortic and pulmonic valves closing during breathing. The electrocardiogram offers a very important source of clinical information, as do blood tests for cardiac enzymes, dissolved gasses, and cell counts. Non-invasive automated methods exist for measuring blood pressure, hemoglobin oxygenation, and pulse rate. Many of these methods pre-date modern cardiac imaging and remain very important today because they are convenient and inexpensive. However, imaging methods offer the unique possibility of interpreting cardiac function directly from anatomical structure, which is possible because the heart acts primarily as a pump.

Average blood flow, as parameterized by cardiac output (CO) is perhaps the single most important parameter for the heart, directly reflecting its primary function of moving blood. The CO, measured at differing levels of physical activity or under the influence of drugs, pacemakers, or other therapies, provides an overall profile of cardiac function in the context of patient care. It is possible to compute the CO from a series of cardiac images by first determining stroke volume (SV), defined as the difference between end-systolic volume and end-diastolic volume. Assuming competent valves, CO is simply the product of SV and pulse rate. Another important use of end-diastolic volume is for the diagnosis of congestive heart failure, in which the heart is overloaded prior to each contraction.

Measuring ventricular volume can be accomplished by a number of imaging modalities besides RT3D ultrasound, as well as by several invasive methods based on catheters. The most important of these will be reviewed in the following section. Their application to measuring volume is generally better established for the LV than the RV, and these differences

will be addressed. Particular advantages and limitations of RT3D ultrasound will be highlighted.

Biplanar Angiography

Biplanar angiography, once considered the gold standard, projects X-rays onto a phosphor screen and captures a moving projection of the patient as a video signal. It requires injection of a contrast agent, usually from a catheter placed directly into the heart. The procedure carries a serious risk to a small but significant percentage of patients. Supplying information about both flow and anatomy, biplanar angiography delivers excellent spatial resolution and high speed in two simultaneous projections from which LV volume may be calculated using geometric assumptions. Errors arise from imprecise estimation of obliquity and heart position along the X-ray beam, as well as from inaccuracies in the geometric assumptions for a given patient (Dodge, Sandler et al. 1960; Wynne, Green et al. 1978). Angiography is unmatched for the study of coronary arteries, aneurysms, pseudo-aneurysms, aortic dissection, and many congenital defects. However, since it projects 3D information onto a plane, biplanar angiography cannot completely capture the non-convex crescent shape of the RV.

X-ray Computerized Tomography

X-ray Computerized Tomography (CT) also uses an X-ray source, but instead of using a single detector, a linear array of detectors is mounted on a ring across the patient from the source, and the whole assembly rotates around the patient. Projection data from transmitted x-ray through the patient thus gathered are tomographically reconstructed to form image slices through the body. The CT images represent attenuation data of the tissues. 3D images are compiled from multiple rings or by sliding the patient through a single ring.

Contrast agents can be used in CT as in angiography to delineate the cardiac chambers as well as the coronary arteries, although the relatively slow imaging speeds of conventional CT impede the ability to analyze heart wall motion without gating to the ECG, thereby reconstructing an "average" cardiac cycle from acquisitions over many actual cardiac cycles.

Cine Computerized Tomography, or "cine-CT" (Rumberger and Bell 1992) uses a device marketed by Imatron, Inc., to produce CT images at higher speeds than conventional CT. Unlike conventional CT in which the X-ray source and sensors are mechanically rotated around the patient, the sensors in cine-CT are fixed in a complete ring while the electron beam

generating the X-rays is spun electronically within a large evacuated cone at the patient's head. Cine-CT can achieve speeds of up to 50 milliseconds per slice. By capturing eight slices with multiple rings of detectors, cine-CT can sample the entire heart volume in 400 ms, or about half a second. Such imaging speeds are still not quite fast enough to accomplish beat-to-beat volumetric studies without gating to the electrocardiogram (ECG) for anything more than a few simultaneous slices. Even with these restrictions, however, cine-CT is a true 3D imaging modality suitable for RV as well as LV study.

Nuclear Imaging

In nuclear imaging of the heart, radioactive agents are injected into a peripheral vein and the resulting radiation is used to form images, primarily of myocardial perfusion but less commonly of the ventricular blood pool. Either of these permit delineation of ventricular boundaries and computation of ventricular volume (Maddahi, 1998). Absolute scintillation counts of radioactivity can also be collected to yield a direct estimate of ventricular volume (Al-Khawaja, Lahiri, et al., 1988).

The three primary methods of cardiac nuclear imaging are (1) planar scintigraphy, (2) single photon emission computed tomography (SPECT), and (3) positron emission tomography (PET). In planar scintigraphy, a 2D array of sensors, called a *gamma camera*, gathers projections of radiation from beta-emitting isotopes. The technique suffers from poor resolution and the overlap between structures. In SPECT, multiple gamma cameras are rotated around the patient and cross-sections are reconstructed in a manner similar to CT. Improvements in resolution are achieved via compensation for attenuation and scatter. The 3D nature of SPECT avoids the problem of overlap between structures. In PET, radiation from positron-emitting isotopes is detected simultaneously by pairs of sensors in a ring around the patient and cross-sections through the patient are reconstructed. None of these methods is rapid enough to study an individual cardiac cycle without gating to the electrocardiogram.

Magnetic Resonance Imaging

Magnetic Resonance Imaging (MRI) uses a strong magnetic field and radio frequency energy to parameterize tissue-dependent interactions between protons and their environments. Inherently a 3D modality, location in an MR image is determined by controlling spatial gradients in the magnetic fields. A variety of capabilities make MR extremely powerful for

cardiac studies. The ability to measure flow directly in three dimensions as well as hemoglobin oxygenation make MR very appealing for both LV and RV study (Debatin, Nadel et al. 1992; Matsumura, Nakase et al. 1993). A technique called *tagging* depletes portions of heart tissue of signal in a regular pattern that lingers long enough to deform with the tissue, permitting tracking of individual portions of the myocardium over the cardiac cycle. Successively faster MRI techniques have evolved in recent years, but even the fastest present methods still have imaging times for 3D studies on the order of seconds. Thus cardiac MR remains dependent upon gating. Cardiac MR is still not widely used in the clinical setting.

Dynamic Spatial Reconstructor

The *Dynamic Spatial Reconstructor* (DSR) is an experimental apparatus that deserves mention, being the only method besides RT3D ultrasound capable of real time 3D cardiac imaging. It was constructed for research (and recently decommissioned) at the Mayo Clinic and was too expensive for general clinical use. The DSR incorporated aspects of fluoroscopy and CT, using multiple X-ray sources and fluoroscopic screens to gathered 3D data in real-time (Robb 1983). During its many years of operation, the DSR gathered unique and valuable data for research in cardiac dynamics and for validation of other methods of measurement.

Conductance Catheter

Before proceeding to ultrasound, it is important to include several *non-imaging* techniques for determining cardiac output. One such technique is the *conductance catheter*, which depends on measuring electrical conductance between two electrodes in the ventricle. This conductance, primarily through the blood, increases with greater ventricular volume because of greater blood cross-section between the electrodes, assuming constant conductivity of blood (J. Baan, E.T. van der Velde et al. 1984). An arterial catheter with multiple concentric electrodes is fed through the aorta into the left ventricle, and conductivity between pairs of electrodes is measured during cardiac contraction. Conductance paths that pass outside the ventricular wall can cause errors, but these extra-ventricular paths can be measured *in vitro* by removing all the blood from the ventricle with suction, or extrapolated *in vivo* by changing the conductance of the blood with saline injections. Such errors are less worrisome when calculating CO, which represents the difference between two volume measurements. Unfortunately, the conductance catheter is plagued by gross inaccuracy and hence is not used clinically.

Swan-Ganz Catheter

In acute clinical settings, the most widely used non-imaging method of measuring CO is the Swan-Ganz catheter, which is fed sequentially through the right atrium (RA) and RV from the venous system, to be wedged into an artery in the lung. It is primarily used to measure left atrial pressure across the low resistance capillary beds of the lung. Simultaneously, a measurement of CO is made by thermodilution, using a small heating element mounted near the tip. The heating element warms the blood as it passes, and subsequent cooling caused by flow is recorded by a temperature sensor mounted further along the same catheter. The Swan-Ganz catheter is effective for measuring both CO and left atrial pressure but is quite invasive.

Implanted Sonomicrometers

In cases when surgery for experimental purposes is acceptable, it is possible to assess ventricular volume using multiple ultrasonic transducers implanted directly in the pericardium or myocardium. Distances between individual transducers, determined for each pair by measuring the time-of-flight of ultrasonic pulses, are combined to compute cardiac geometry based on known initial placement of the transducers. Sequencing through the transducers is rapid enough to permit continual measurements while the heart is beating. If the transducers are placed in the epicardium, calculating chamber volume requires compensation for heart wall thickness, but such errors tend to cancel each other out in the calculation of SV because the volume of the myocardium remains essentially constant during contraction. Geometric assumptions about chamber shape permit calculation of volume of LV and RV from a relatively few number of elements. Implanted sonomicrometers are useful for *in vivo* experimental preparations to gauge the accuracy of other less invasive methods of volume measurement (Stetten, Irvine et al. 1999 (in press)).

2D Ultrasound

This review now returns to imaging to discuss ultrasound in particular. Ultrasonic images are produced from directional transmission and reception of acoustic energy in the megahertz range. Intensity in such images corresponds to the strength of echoes from within the body.

Ultrasound is a natural modality for cardiac imaging. Its speed, range, field of view, and resolution are well matched to the task. This was quickly recognized by the builders of the early linear-array scanners in the 1970's, who produced the first B-mode images of the beating heart. B-mode images are basically sectors of a disk, such as would be a complete disk in a sonar image (see Fig. 2.1A) (von Ramm 1973; von Ramm and Thurstone 1976). Because of its ability to provide real-time information about anatomy and flow, as well as its safety, portability, and relatively low cost, linear array ultrasound is today the most prevalent method of diagnostic imaging in clinical cardiology.

A linear-array scanner uses a row of transducers to steer an ultrasound beam within a single slice of tissue. By controlling the signal delays between individual transducers, the transmitted and received ultrasound energy can be made to focus much the same way light is focused by a lens. The dynamic nature of this electronic "lens" permits rapid sweeping along the azimuth dimension while focusing along the range dimension.

Reflections of ultrasound energy within the body are produced by spatial discontinuities in acoustic impedance. Such reflections are anisotropic in nature, depending on the orientation of the discontinuities with respect to the ultrasound beam. This anisotropy is evident in image textures generated within a tissue and may cause dropout of boundaries between tissues along the ultrasound beam.

Such dropout notwithstanding, a cross section of the ventricular boundary is usually discernible in a B-mode slice and may be used to extrapolate the entire 3D shape of the ventricle by making assumptions about its shape and location with respect to the slice (Moritz, Pearlman et al. 1982; Fazzalari, Davidson et al. 1984). For example, from a 4-chamber view along the axis of the LV, the 3D shape of the entire ventricle can be extrapolated, by assuming it to be a truncated ellipsoid. The CO can then be calculated from changes in volume between diastole and systole.

Several serious sources of error arise from determining ventricular volume in this manner. The geometric assumptions are fundamentally inaccurate and insensitive to anatomic variation. When considering time sequences of images, another source of error arises due to *through-plane motion*, caused by changes in the location and orientation of the heart relative to the slice. For example, the endocardial boundary seen in a cross section may appear to be contracting when actually the slice has simply moved closer to the LV apex, where the chamber is

narrower. Through-plane motion is even more serious in the RV, where the complex shape of the chamber does not slice well to begin with. These problems are solved by 3D ultrasound, as described below.

Besides providing anatomical information, ultrasound is also capable of measuring velocity (of blood or tissue) based on the Doppler effect. Doppler systems have been developed for both 2D and 3D ultrasound scanners. They are inherently limited to motion in the range dimension, since motion across the ultrasound beam does not generate any Doppler effect. This limitation is a serious impediment to estimating total flow for CO.

An experimental method for measuring total blood flow depends on tracking *speckle*, the local signature caused by differences in coherence between multiple reflectors (such as red blood cells) within each resolution cell (Trahey, Allison et al. 1987; Bohs, Friemel et al. 1993). These signatures survive over time for a given patch of blood, and can be used to track its motion both along and across the ultrasound beam. The method has been under development in 2D and has recently been demonstrated in 3D for speckle maxima in heart wall tissue. Once made practical, the combination of speckle tracking and 3D ultrasound may provide a method of determining not only CO but an entire spatio-temporal profile of blood flow within the heart.

Reconstructed 3D Ultrasound

The obvious benefits of gathering 3D data with ultrasound have driven researchers to develop mechanical systems to sweep or rotate linear-array devices through the third dimension (Moritz, Pearlman et al. 1982; Geiser 1985; Raichlen, Trivedi et al. 1986; Zoghbi, Buckley et al. 1990; Gopal, King et al. 1992). The major problem with creating 3D data sets in this manner is the significant time between slices required to mechanically move the array. Thus, respiration, patient motion, and the cardiac contractions themselves, cause misalignment in the 3D reconstruction. Furthermore, because of the time involved, gating is still required. With RT3D ultrasound, as described in the following section, these problems are eliminated by the nearly instantaneous nature of the data acquisition.

Real Time 3D Ultrasound

RT3D ultrasound is a new imaging modality developed at Duke University in the early 1990's (Stetten, Ota et al. 1998). The RT3D scanner electronically interrogates a volume in 3D using a *matrix array* of transducers (Fig. 2.1A) instead of a conventional linear array (Fig.

2.1B) (Ramm, Pavy et al. 1991; Sheikh, Smith et al. 1991; Smith, Henry G. Pavy et al. 1991; von Ramm, Smith et al. 1991; Smith, Pavy et al. 1992). The resulting data "pyramid" can be sliced into orthogonal "B-mode" images, or into "C-mode" images which are parallel to the transducer (Fig. 2.1C). Unlike 3D ultrasound techniques that rely on physically moving a linear array, the scan rate of matrix array ultrasound is rapid enough (22 frames/second) to smoothly sample heart wall motion during a single cardiac cycle. Thus, gating to the electrocardiogram (ECG) and averaging the acquisition over multiple cycles is no longer required. This continuous and rapid scanning of the heart is described as *real time* to differentiate it from other 3D studies that require ECG gating.

RT3D data has formed the basis of recent studies detecting ischemic risk (Ohazama, Stetten et al. 1996, (in press); Fleishman, Ota et al. 1996, (submitted); Hsieh, Collins et al. 1996, (submitted)), determining LV mass (Fleishman, Ota et al. 1996, (submitted)), detecting congenital defects (Fleishman, Li et al. 1996, (submitted)), and measuring ventricular volume with manual or semi-automated methods (Ota, Fleishman et al. 1996; Ota, Fleishman et al. 1996; Ota, Fleishman et al. 1997; Ota, Ohazama et al. 1997 (accepted)). A recent increase in the number of available RT3D scanners (20 have so far been sold to major hospitals in the US and abroad) suggests that many new research projects are currently underway.

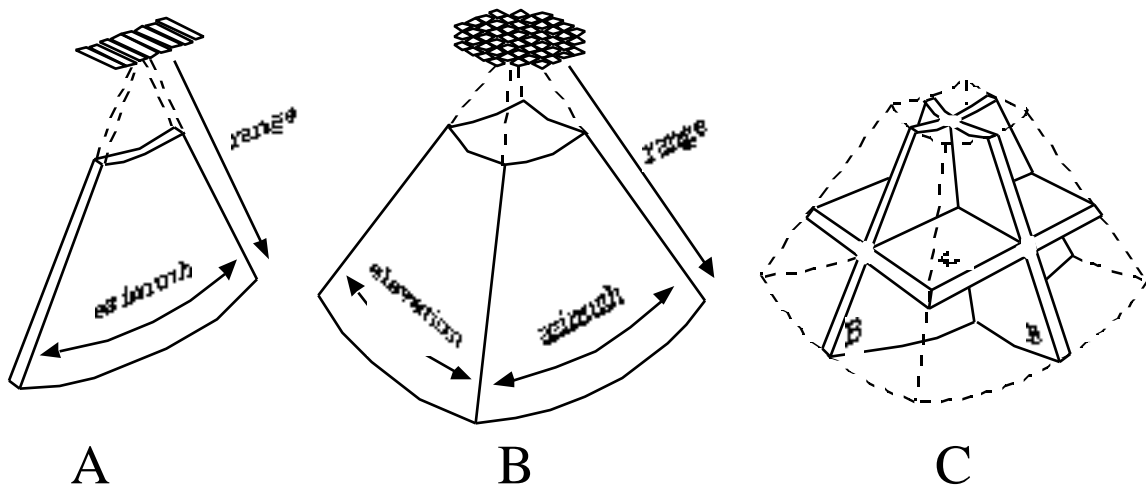


Fig. 2.1 **A.** Conventional 2D ultrasound uses a linear array to steer within a slice, producing a B-mode image. **B.** Real Time 3D ultrasound uses a matrix array to scan a volume without moving the transducer. **C.** Two orthogonal B-mode slices, and one C-mode slice (parallel to the transducer) within the 3D ultrasound pyramid.

However, fully automated analysis of even the simplest anatomical parameters such as LV volume has not yet been achieved. Such automation would permit continuous determination of

left ventricular volume, which would inherently include such widely used parameters as *heart rate*, *stroke volume*, and *ejection fraction*. Assuming competent valves, continuous ventricular volume could also be used to calculate *cardiac output* and the previously elusive measurement of *end-diastolic volume*, which is central to the diagnosis of congestive heart failure. Beyond LV volume, further parameterization of other cardiac parameters such as wall motion and wall thickness could aid in many forms of heart disease including arrhythmia, ischemia, and infarction.

2B. Approaches to Analyzing Cardiac Shape

While an exhaustive comparison of the numerous methods developed for object recognition and measurement is beyond the scope of this paper, the majority of researchers in recent years have chosen deformable models for locating the cardiac ventricle, based either on contours (2D) or surfaces (3D). Deformable models constitute a *top-down* approach in which an iterative search for likely boundaries is constrained by prior knowledge about the expected shape. They have generally fallen into two categories: (1) snakes, which contain only local geometric expectations (McInerney and Terzopoulos 1996) and (2) deformable models with multi-local or global geometric or probabilistic expectations (Pizer, Fritsch et al. (in press); Cootes, Taylor et al. 1994; Szekely, Kelemen et al. 1996). Recent examples include deformable surfaces applied to 3D cardiac data from the Dynamic Spatial Constructor (DSR) (Robb 1983) using Fourier (Staib and Duncan 1996; Clarysse, Friboulet et al. 1997) and superquadric (Bardinet, Cohen et al. 1996) based parameterizations. Deformable surfaces based on physical models have been applied to tagged MRI data (Park, Metaxas et al. 1996).

Methods of finding and measuring the LV using 2D data from conventional ultrasound scanners have likewise concentrated on deformable contours (Hunter, Soraghan et al. 1993; Chalana, Linker et al. 1996; Hozumi, Yoshida et al. 1997; Mikic, Krucinski et al. 1998; Malassiotis and Strintzis 1999). Deformable surfaces have been applied to mechanically scanned 3D echocardiographic data by at least one researcher (Coppini, Poli et al. 1995). Attempts at applying deformable methods to RT3D ultrasound, with its even lower data quality, has not produced encouraging results (Stetten, Irvine et al. 1999 (in press)). The difficulties encountered along this avenue led to a review of *bottom-up* approaches based on the measurement of geometric image properties.

One such approach has yielded particularly successful fully automatic detection of the LV in 2D ultrasound data. In this method circular arc matched filters are used to find cross sections of the ventricle (Wilson, Geiser et al. 1993). Other successes have been reported in 2D

ultrasound using a version of template matching to find the center of the ventricle and then fuzzy reasoning to find the boundary (Feng, Lin et al. 1991). In recent research along the same lines, a Hough transform approach has been developed using circular edge filters that yields fully automated measurement of balloons in RT3D data (Stetten, Caines et al. 1995; Stetten and Morris 1995). All of these approaches possess fundamentally medial aspects, that is, they relate multiple boundary points to common central points deep within the object. The preliminary success with the RT3D ultrasound data has led to an exploration of the generalized medial approach developed in this dissertation, which extends to more complicated shapes and differentiates medial relationships between boundary points into several fundamental types.

2C. The Medial Lineage

The lineage of the medial approach may be traced to the medial axis (otherwise known as the symmetric axis or skeleton) introduced on binary images by Blum and developed by Nagel, Nackman, and others (Blum and Nagel 1978; Nackman 1982; Nackman and Pizer 1985). Pizer has extended the medial axis to gray-scale images producing a graded measure called medialness, which links the aperture of the boundary measurement to the radius of the medial axis to produce what has been labeled a core, which is defined as a height ridge of medialness which is a locus in a space of position, radius, and associated orientations (Burbeck and Pizer 1995; Pizer, Eberly et al. 1998). Methods involving these continuous loci of medial primitives have proven robust against noise and variation in target shape (Morse, Pizer et al. 1998).

Determining a core has been accomplished by ridge tracking, which has the computational advantage that only a limited region need be processed, namely, the leading edge or tip of the ridge (Furst and Pizer 1998; Furst and Pizer June 1996). Ridge tracking generally requires initialization and suffers from stopping at breaks in the ridge. It is also not generally governed by higher-level models of shape corresponding to complex anatomical structures. Filters used in ridge tracking to measure medialness must look for multiple boundaries simultaneously. They may be isotropic, in which case boundariness is measured at a given distance from the center without any preferred orientation. These filters have the computational advantage of needing to be applied only once but in general are less sensitive at discerning medialness than oriented filters. Oriented filters look for pairs of boundaries with a particular orientation from the center. To deal with different orientations they must be applied multiple times. This is computationally expensive, especially in 3D.

Higher level models relating multiple discrete medial primitives have provided the framework for a class of active shape models known as *deformable m-reps* (sampled medial representations) (Pizer, Fritsch et al. (this issue); Fritsch, Pizer et al. 1997). Placed into the

image space, usually manually, they attempt to optimize the match of the constituent medial primitives while penalizing deformation of the model. They suffer from getting snagged on intervening objects or being initialized out of their capture range. Despite being less sensitive than other deformable models in regard to these behaviors, they still exhibit the behaviors to some degree.

To give the medial approach a more *bottom-up* flavor, the method developed in this dissertation depends on analyzing medialness throughout the image first, and then matching disconnected locations with adequately high medialness against nodes in a model. The locations are identified by first searching for individual boundary points throughout the image in an initial sweep, and then finding pairs of boundary points suitable for core atom formation. A *core atom* is so named because it is the *smallest indivisible unit for medialness*, that unit being a single pair of boundary points with high enough medialness to pass a certain threshold. The core atom is a constrained version of what Pizer, et al., call the *medial atom* (Pizer, Thall et al. (submitted 1999)).

Core atoms tend to form in clouds along the core. Statistical analysis of populations of core atoms can extract the local properties of scale, orientation, and dimensionality (shape type) of local pieces of the core, as described in Chapter 3. Once these properties have been measured throughout the image, only then are they matched against a model to identify more complex objects. Core atoms were developed first for analysis of uncluttered 2D shapes without localization (Stetten, Landesman et al. 1997) and then generalized to 3D with provision for spatially sampled populations to differentiate local portions of the core (Stetten and Pizer 1998; Stetten and Pizer 1999 (accepted); Stetten and Pizer 1999 (in press)).

2D. Method Overview

In the following chapters, statistical analysis of core atoms will be developed with the driving problem of identifying and measuring the LV in mind. There will be several interim goals along the way including parameterization of basic test shapes and volume measurement of fluid filled balloons using RT3D ultrasound. A model of the heart will be developed as shown in Fig. 2.2. An apical scan of the LV during systole shows it essentially to be a large cylinder with an apical cap at one end, and a slab-like mitral valve (MV) at the other. This model is an example of a proposed class of models called *medial node models*, capable of describing more complicated anatomical structures.

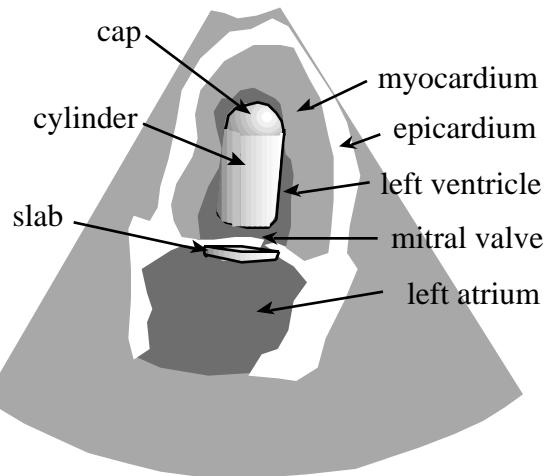


Fig. 2.2 Model of left ventricle and mitral valve

Given the model in Fig. 2.2, the overall method to identify and measure the LV can be defined in terms of the apex-to-mitral-valve (AMV) axis, which extends from the apical cap to the center of the mitral valve at the center of the ventricular cylinder. The method is outlined in Fig. 2.3 and proceeds as follows to satisfy the goals of the dissertation: Boundary points are found and core atoms formed from appropriate pairs of the boundary points. Populations of core atoms are analyzed statistically and clustered in a manner that reflects the underlying cores. Individual clusters are matched against individual nodes in the model representing the LV and MV, and then pairs of clusters are found that satisfy geometric constraints between the two nodes. Given the axis between the LV and MV clusters, the cap of the LV is sought yielding the AMV axis. Using the AMV axis as a prior, voxels in the region are assigned a probability of being in the LV based on their intensity, and a probabilistic volume of the LV computed.

Overview of Method for Finding AMV Axis

3A

Find core atoms from pairs of candidate boundary points

3C

Extract local shape properties from regularly sampled populations of core atoms

4

Remove sampling artifact by ellipsoidal voting to cluster core atom samples

5A

Match LV and MV clusters to individual nodes in the model.

5B

Match LV,MV pairs of cluster pairs to node pairs in the model.

5C

Extend the LV,MV axis to the LV apex

7B

Determine volume of LV

Fig. 2.3 Overview of method to find the apex-to-mitral-valve (AMV) axis, with associated chapters and sections where the method is developed. Chapter 8 describes the actual experiment.